

# ULTRA-HIGH FREQUENCY ULTRASOUND IN MELANOMA MANAGEMENT: A NEW COMBINED ULTRASONOGRAPHIC-HISTOPATHOLOGICAL APPROACH



Teresa Oranges<sup>1,2</sup>, MD, PhD; Agata Janowska<sup>2</sup>, MD, PhD; Cristian Scatena<sup>3</sup>, MD, PhD; Francesco Faita<sup>4</sup>, MSc, PhD; Nicole di Lascio<sup>4</sup>, MSc, PhD; Rossana Izzetti<sup>3</sup>, MD, PhD; Cristian Fidanzzi<sup>2</sup>, MD; Marco Romanelli<sup>2</sup>, MD, PhD; Valentina Dini<sup>2</sup>, MD, PhD



<sup>1</sup> Dermatology Unit, Department of Pediatrics, Meyer Children's Hospital, Florence, Italy. Email: [teresa.oranges@gmail.com](mailto:teresa.oranges@gmail.com).

<sup>2</sup> Department of Dermatology, University of Pisa, Pisa, Italy.

<sup>3</sup> Department of Translational Research and New Technologies in Medicine and Surgery, University of Pisa, Pisa, Italy.

<sup>4</sup> Institute of Clinical Physiology, National Research Council, Pisa, Italy.

**Background:** The ultra-high frequency ultrasound (UHFUS) has been recently described as a new promising tool for differential diagnosis of melanocytic lesions.<sup>1,2</sup> The main aim of this study is to evaluate the correspondence between the ultrasonographic thickness and the Breslow thickness in melanoma using UHFUS and the intra- and inter-operator repeatability in the ultrasonographic measurements of melanoma depth. Moreover, we propose a new protocol based on a combined ultrasonographic-histopathological approach.

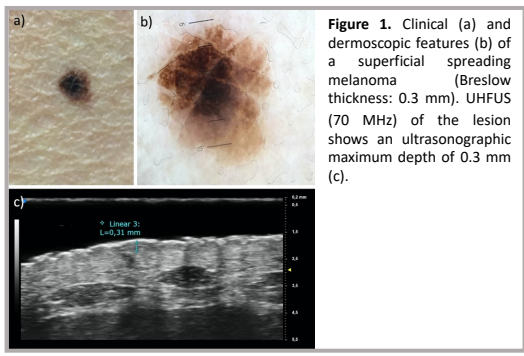
**Methods:** We analysed 27 melanomas in 27 patients (mean age 57.6 years, 51.8 % males), who had an ultrasonographic examination of a suspected melanocytic lesion before the surgical removal using UHFUS (VevoMD, Fujifilm, Visualsonics, Toronto, Canada; 70 MHz probe). B-mode images were analyzed by two skilled and blinded operators, and the maximum depth of the lesions was measured using a dedicated graphical user interface developed in Matlab R2016b (MathWorks Inc., Natick, MA, USA), to obtain repetitive measurements. Each operator repeated the assessment on three different frames to measure the intra-session variability. The whole evaluation was performed again one day after the first evaluation in order to measure the inter-session repeatability. For each lesion, the final depth measured by each operator was obtained as the mean value of the assessments performed during the two measurement sessions. The evaluations obtained by the two operators were compared in order to assess inter-operator variability. The final depth values of the melanomas obtained by each operator, as well as those obtained as the average value of the two operators' assessments, were compared with the Breslow index obtained from the histological evaluation. The two measurements were assessed by the Pearson correlation coefficient and Bland-Altman analysis was also performed. All the statistical tests were considered significant for  $p < 0.05$ . SPSS v. 23 (IBM, New York, NY, USA) was used for all statistical analyses<sup>3</sup>.

**Results:** All melanomas appeared as band-like or oval/fusiform shaped hypoechoic inhomogeneous lesions. We observed an excellent agreement between the Breslow thickness of melanomas and the ultrasonographic thickness (Fig. 1a-c), as well as a reduced intra- and inter-operator variability in the ultrasonographic measurements of melanoma depth (Table 1). We propose a new ultrasonographic-histopathological approach based on these results, considering the possibility to identify the point of maximum depth with UHFUS. In the case of suspected atypical melanocytic nevus, an ultrasonographic depth  $\geq 0.8$  mm indicates a high priority in the waiting list for elective surgery, in order to facilitate early melanoma diagnosis. The clinician can mark the point of maximum depth identified with UHFUS using two perilesional stitches (Fig.2). This procedure can guide the pathologist that will be able to perform conventional vertical bread-loafing technique including the section of maximum depth of the lesion, reducing the variability in the analysis of the histopathological Breslow thickness, particularly in the case of large lesions (Fig.3a-d). Clinicians can also use a perilesional stitch to mark any submillimetric intralésional structure detected with UHFUS, ensuring that it don't get lost during the histopathological cutting procedure. Moreover, in case of diagnostic incisional biopsy (e.g. large lentigo maligna/lentigo maligna melanoma on the face), UHFUS can guide the clinicians indicating the point of maximum depth (Fig.2)<sup>3</sup>.

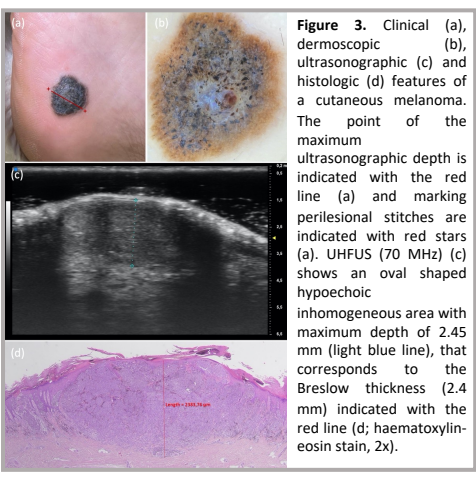
**Conclusions:** UHFUS may have an important role in the pre-surgical assessment of melanomas. We propose a ultrasonographic-histopathological protocol which may help clinicians to reduce the diagnostic delay, improve prognosis and survival rates, perform a surgical excision with negative margins, and reduce the variability in the assessment of Breslow thickness.

	Session 1		Session 2		Sessions 1-2	
	CV (%)	ICC	CV (%)	ICC	CV (%)	ICC
Operator 1	4.8	0.99	4.7	0.99	6.2	0.99
Operator 2	6.7	0.99	6	0.99	5.9	0.99

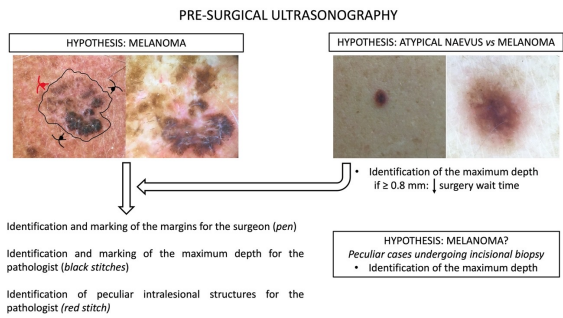
CV: coefficient of variation; ICC: intra-class correlation.  
**Table 1.** Intra- and inter session variability analysis.



**Figure 1.** Clinical (a) and dermoscopic features (b) of a superficial spreading melanoma (Breslow thickness: 0.3 mm). UHFUS (70 MHz) of the lesion shows an ultrasonographic maximum depth of 0.3 mm (c).



**Figure 3.** Clinical (a), dermoscopic (b), ultrasonographic (c) and histologic (d) features of a cutaneous melanoma. The point of the maximum ultrasonographic depth is indicated with the red line (a) and marking perilesional stitches are indicated with red stars (a). UHFUS (70 MHz) (c) shows an oval shaped hypoechoic inhomogeneous area with maximum depth of 2.45 mm (light blue line), that corresponds to the Breslow thickness (2.4 mm) indicated with the red line (d; haematoxylin-eosin stain, 2x).



**Figure 2.** The ultrasonographic-histopathological approach in cutaneous melanomas.

**References:** 1) Janowska A, Oranges T, et al. Ultra-high-frequency ultrasound monitoring of melanomas arising in congenital melanocytic nevi: a case series. *Melanoma Res.* 2021;31:561-5. 2) Faita F, Oranges T, et al. Ultra-high-frequency ultrasound and machine learning approaches for the differential diagnosis of melanocytic lesions. *Exp Dermatol.* 2022;31:94-8. 3) Oranges T, Janowska A, et al. Ultra-high frequency ultrasound in melanoma management: a new combined ultrasonographic-histopathological approach. *J Ultrasound Med.* 2022 [Epub ahead of print].